



Xenolingual Autoeroticism

M. Barry Randall, M.D., Richard P. Vance, M.D., and Timothy H. McCalmont, M.D.

Reports in the medical literature of autoeroticism seldom describe episodes that are nontraumatic or nonlethal. Reports of bestiality typically involve descriptions of sexual relationships between humans and animals, and are analyzed through psychological methods. No reports of bestiality involving the use of animal tissue for erotic purposes have been published. We report the use of a deer tongue as a masturbatory tool.

Key Words: Autoeroticism—Bestiality—Masturbation.

CASE HISTORY

When this 29-year-old woman came to an abortion clinic, she was complaining of missed periods and was seeking termination of possible pregnancy. Upon examination, a cylindrical tissue mass was easily recovered from her vagina. Dilatation and curettage were subsequently performed without complication. Pathologic examination revealed a 7-cm-long, up to 3-cm-diameter, pale-gray tissue mass with a corrugated to papillated mucosal surface and a rounded mucosa-covered tip. The cut surface was moderately firm, homogeneous pale-brown, and appeared muscular. Light-microscopic examination revealed a gently papillated squamous epithelium surrounding delicately interlacing bundles of skeletal muscle (Figs. 1 and 2). Numerous parasitic cysts within muscle fibers were identified (Fig. 3) belonging to the family Sarcocystinae, a protozoan similar in life cycle to *Toxoplasma* (Fig. 4). These represent an asexual cycle in muscle cells in intermediate hosts, commonly *Herbivora* (1). Based on this evidence, further historical information was elicited, confirming that the object was a deer tongue used for masturbation (Fig. 5). Examination of the curetted material revealed no evidence of intrauterine pregnancy.

DISCUSSION

The topic of autoeroticism usually enters the medical literature through reviews or case reports detailing death or injury. Our review of the *Index Medicus* found 42 citations under the heading of autoeroticism: 14 of these detailed various psychological aspects of such practices, and 27 were directly related to deaths arising from autoerotic practices. Only one reference reviewed various nonlethal autoerotic practices (2). Over a 42-year period, Aliabadi et al. recorded 18 patients, only three of whom were women, who presented with foreign-body insertion for erotic purposes. All three

From the Department of Pathology, Wake Forest University, the Bowman Gray School of Medicine, Winston-Salem, North Carolina.

Address correspondence and reprint requests to Dr. B. Randall, Mercy Hospital, Department of Pathology, 2001 Vail Avenue, Charlotte, NC 28207, U.S.A.

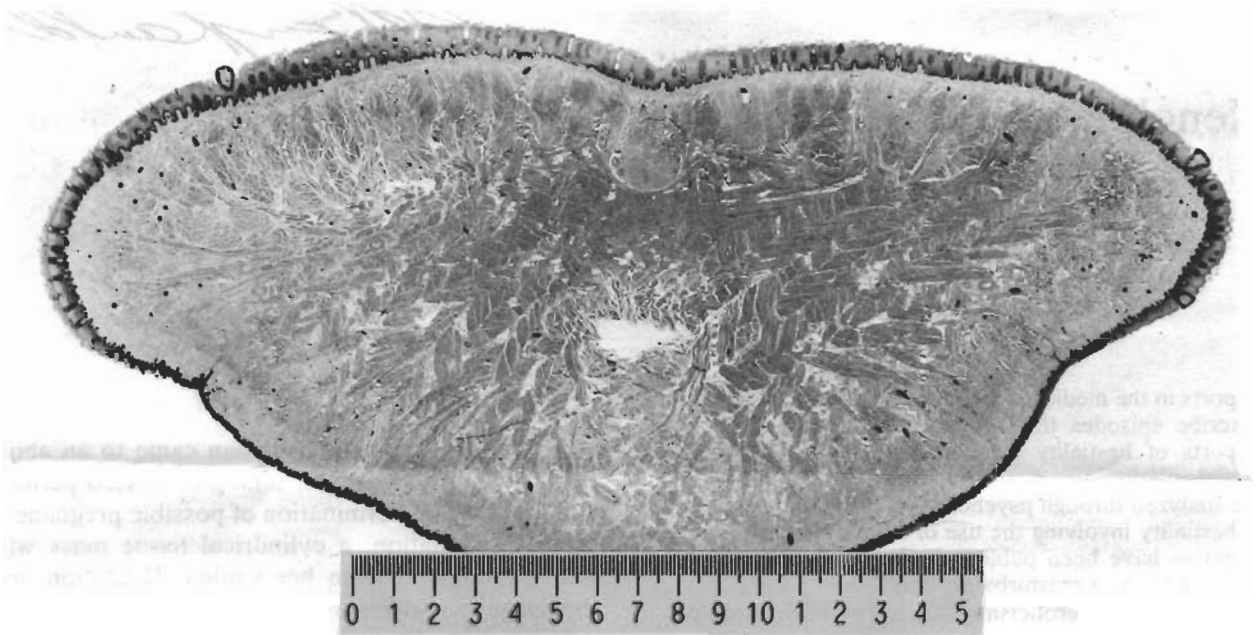


FIG. 1. Macrograph cross section of deer tongue. Hematoxylin–eosin (H&E).

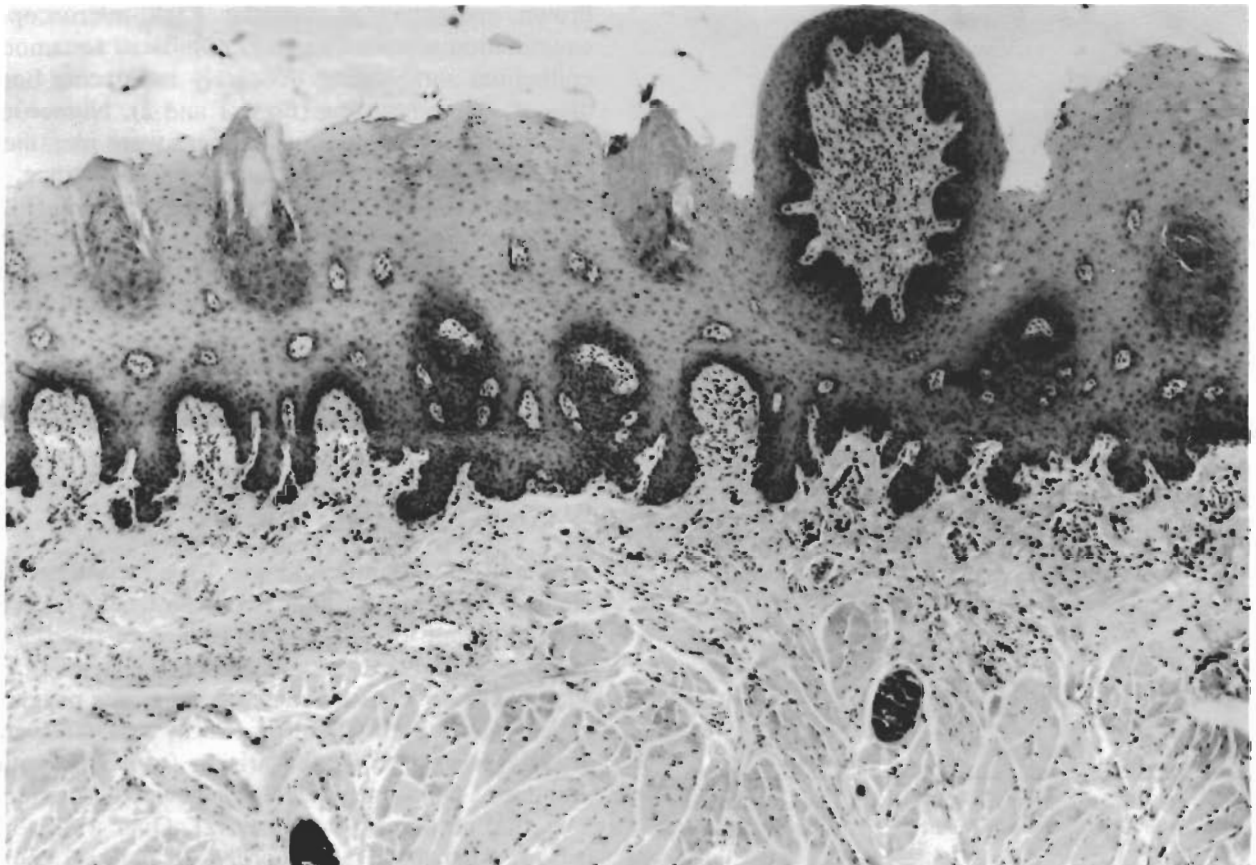


FIG. 2. Papillated squamous mucosa overlying skeletal muscle. Small parasitic cysts are also noted in the muscle. H&E; original magnification, $\times 200$.

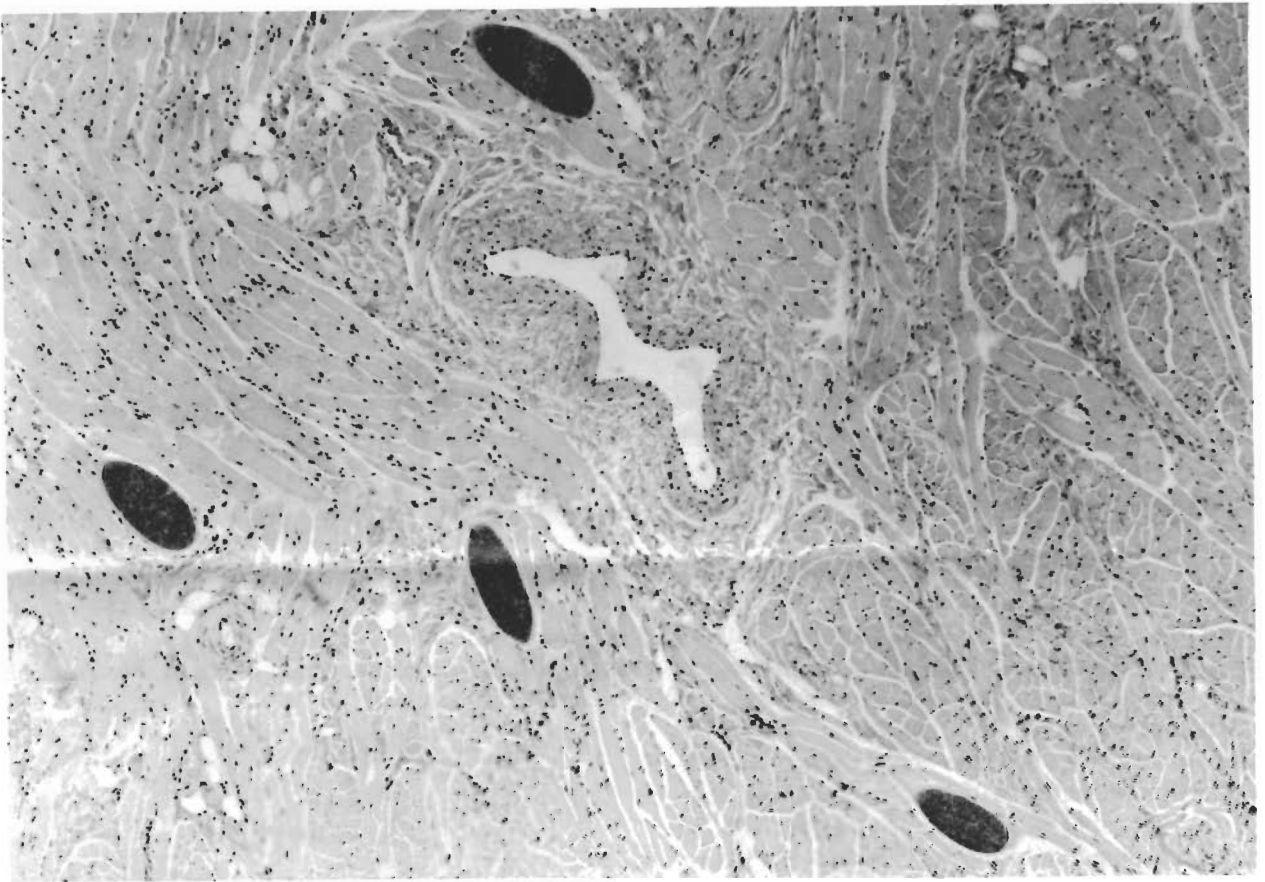


FIG. 3. Parasitic cysts in muscle fibers; representative low-power field. H&E; original magnification, $\times 100$.

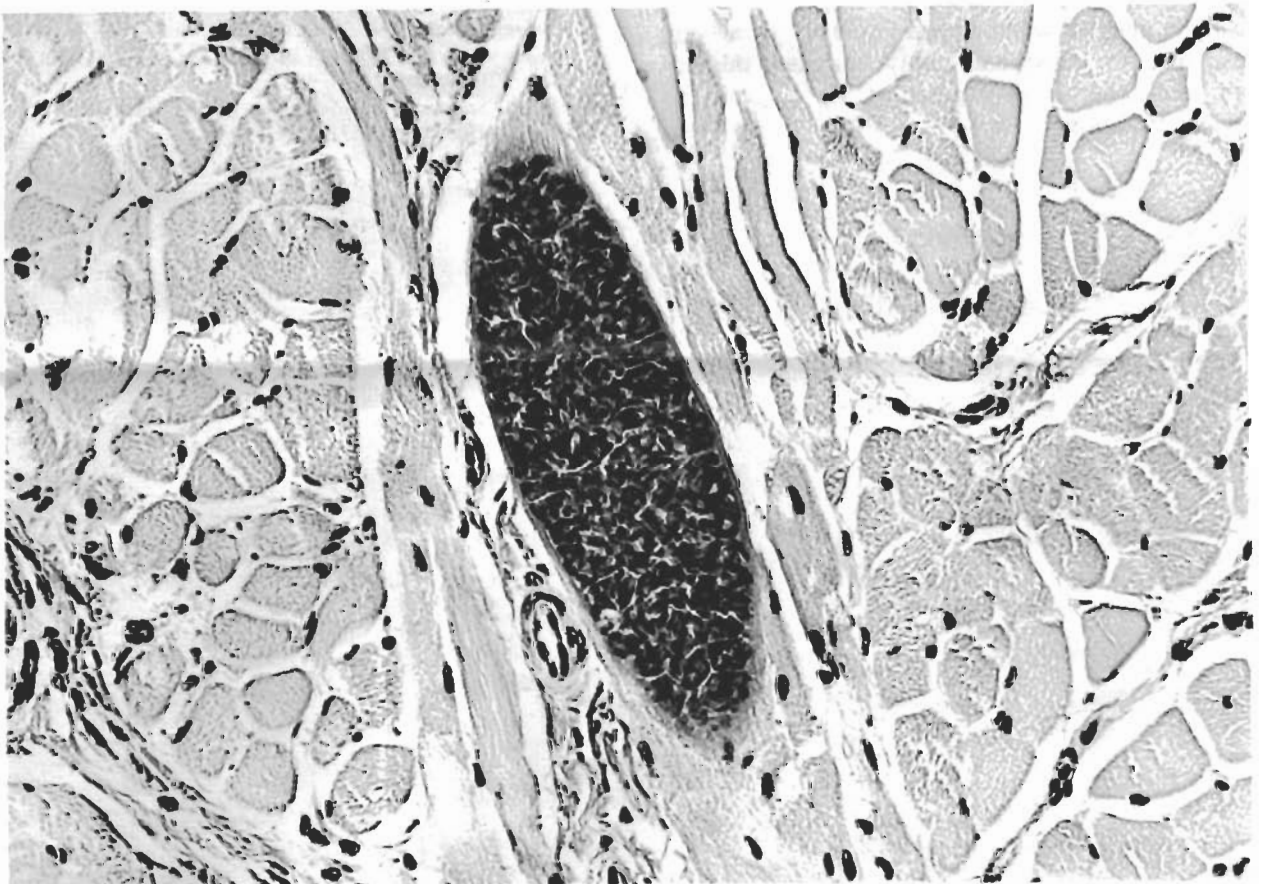


FIG. 4. Parasitic cyst at high power showing detailed internal structure. H&E; original magnification, $\times 400$.



FIG. 5. Gross photograph of a representative deer tongue.

women had inserted foreign bodies into the urinary tract. Acts of **autoeroticism involving vaginal masturbation** with foreign objects are perhaps more common. None to our knowledge have been reported because these do not result in death or injury, and typically would not come to medical attention. The literature discloses examples of foreign bodies extracted from the male and female lower urinary tract because objects of small diameter may be retracted by natural muscular impulses into the proximal urethra and/or bladder (2). Indeed, according to Kinsey and others (3,4) >90% of foreign bodies found in the female bladder or urethra are there as a result of masturbation. Also, large objects retrieved from the vagina are found mostly in married women aged 17–30 (4). However, these objects, most commonly bananas, cucumbers, and other large vegetables, rarely come to surgical attention.

The medical literature reveals only seven references to **bestiality**. None of them deals with the issue of using nonviable animal tissue for autoerotic purposes. This report is presented so that xenosexual objects may be placed on the list of possible masturbatory tools that may come to the attention of medical personnel. □

REFERENCES

1. Jones TC, Hunt RD, eds. *Veterinary pathology*. Philadelphia: Lea and Febiger, 1983:733–9.
2. Aliabadi H, Cass AH, Gleich P, Johnson CF. Self-inflicted foreign bodies involving lower urinary tract and male genitals. *Urology* 1985;26:12–6.
3. Kinsey A. *Sexual behavior in the human female*. Philadelphia: WB Saunders, 1953.
4. Ellis H. *Studies in the psychology of sex*; vol 1. New York: Random House, 1942:171–4.